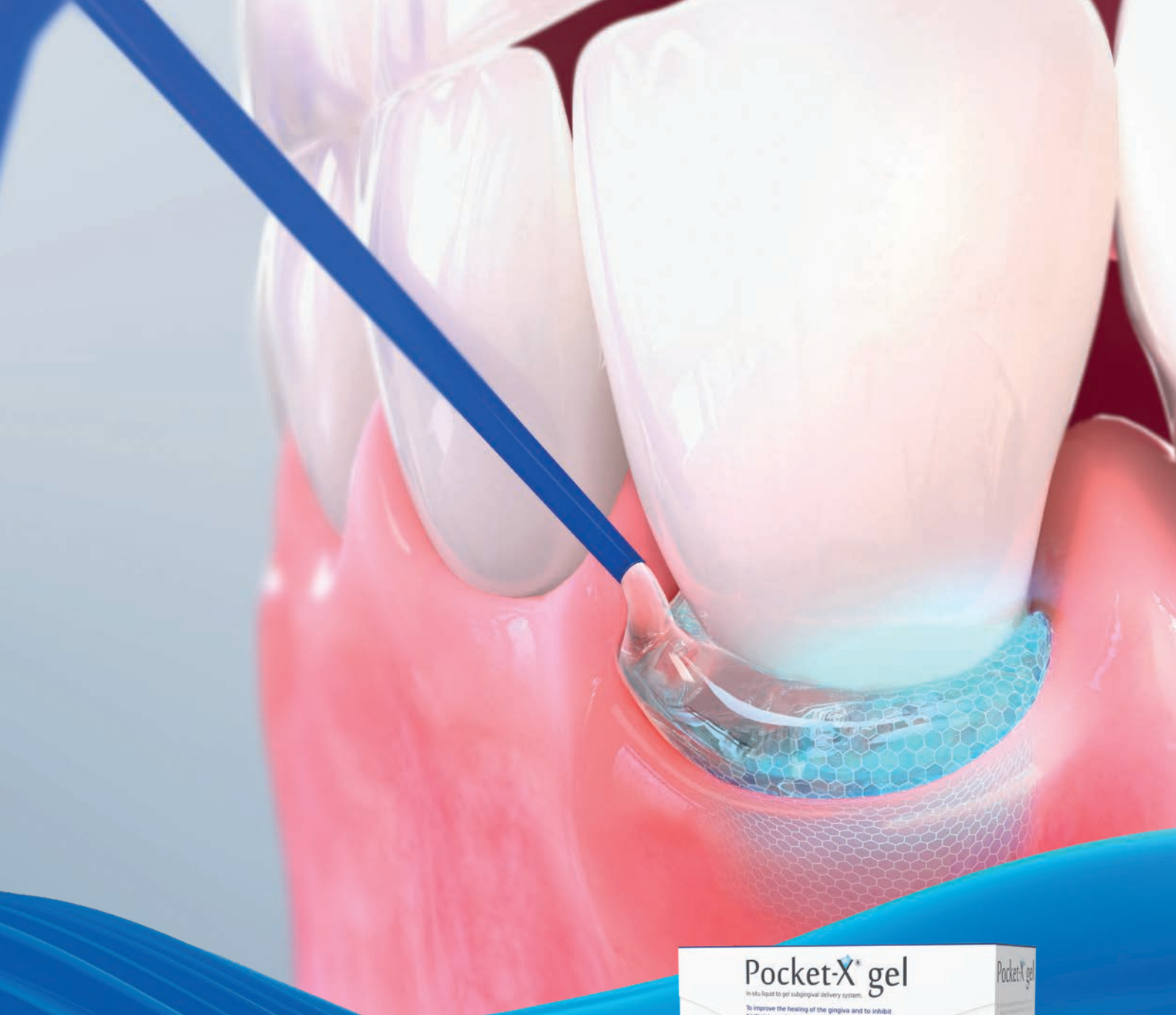



Pocket-X® Gel – Clinical Insights

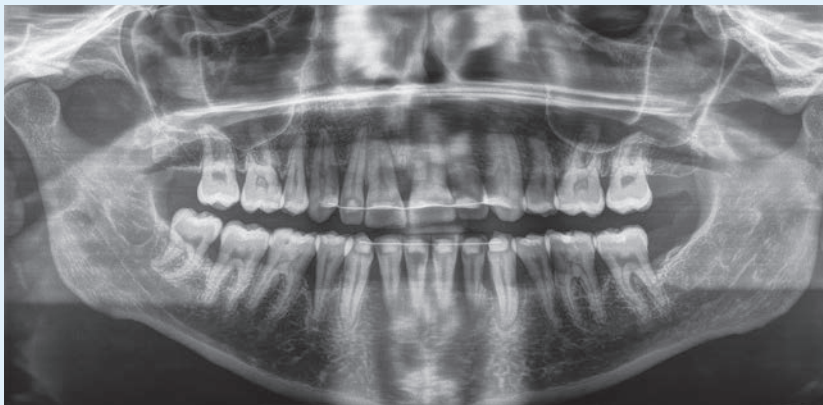
leading regeneration

Geistlich

Insights from Prof. Dr. Peter Hahner

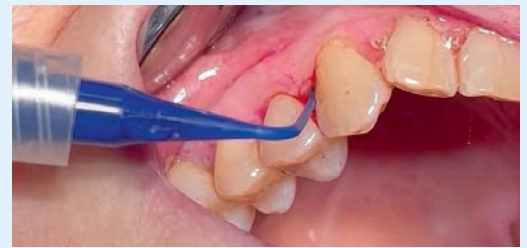

Prof. Dr. Peter Hahner,
Professor of Clinical Periodontology and
Prevention Management at EU FH,
Practice for Periodontology in Cologne



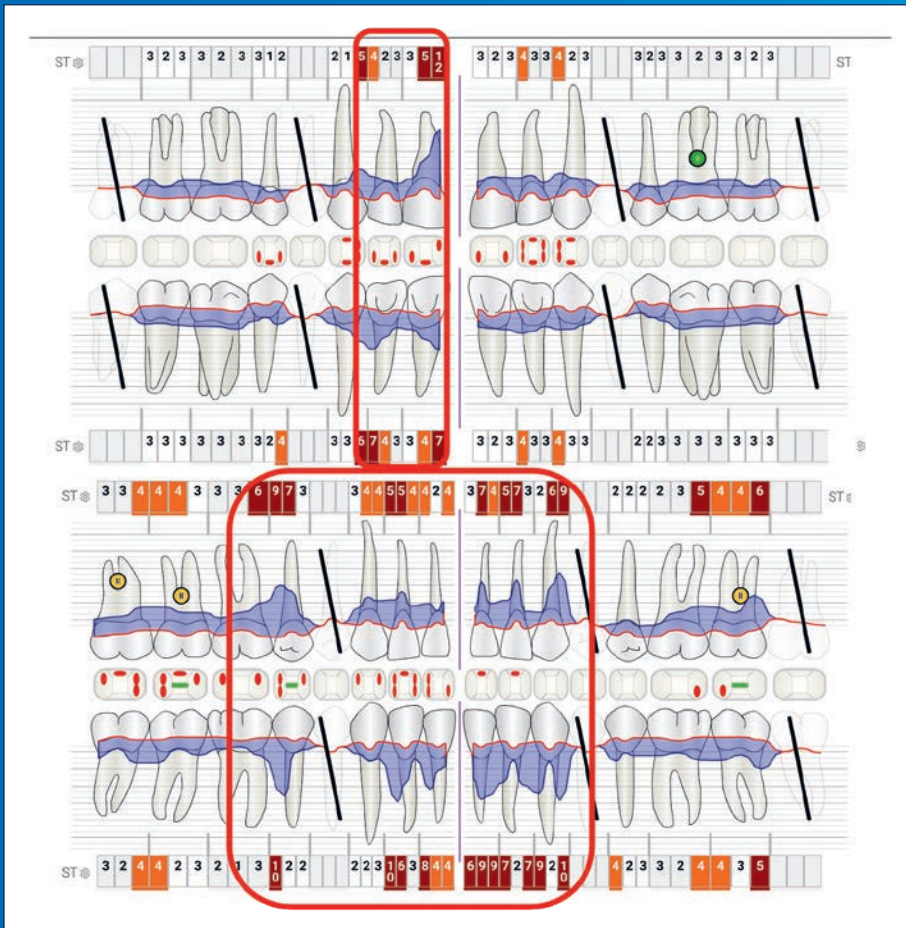
Initial assessment (patient born in 1990)

The X-ray image reveals significant bone loss in several areas. Various non-surgical interventions by previous practitioners failed to halt the progressive tissue breakdown.

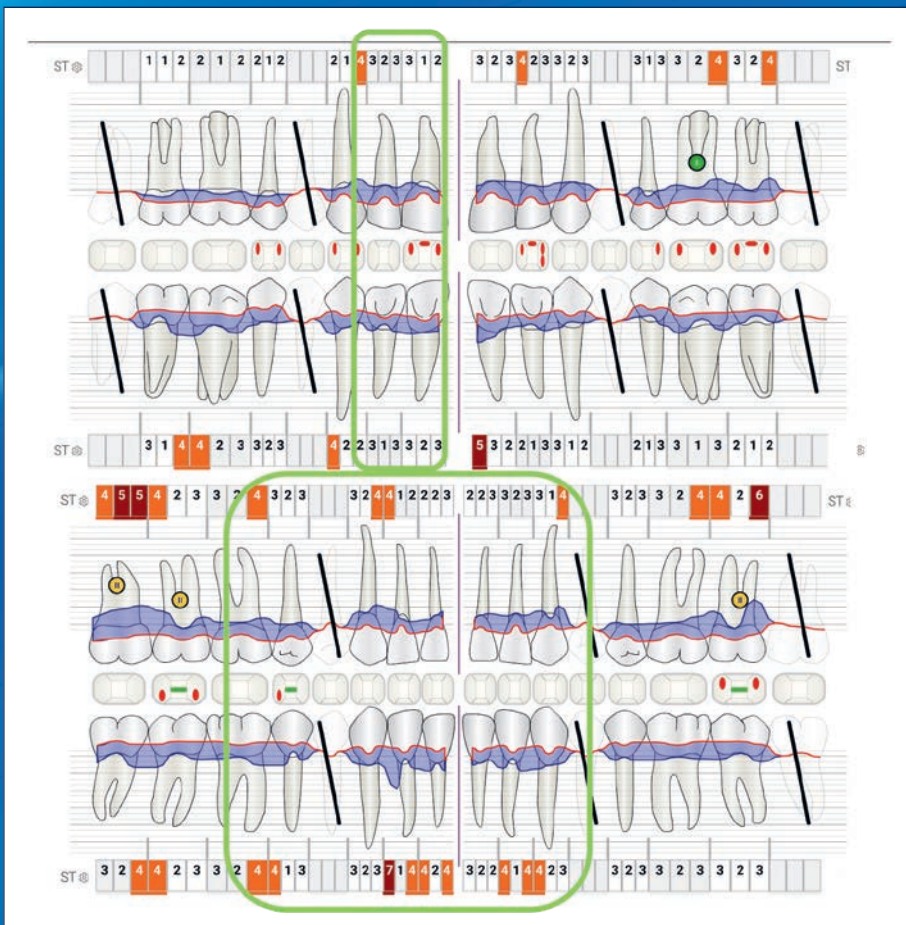


Atraumatic approach as the foundation

For optimal wound healing, an atraumatic approach during subgingival instrumentation appears to be crucial. The illustration (from another patient) exemplifies the results with only minimal bleeding from the periodontal pockets immediately after debridement.



Assessment and treatment (supra- and subgingival mechanical plaque removal as part of supportive periodontal care), including application of Pocket-X® Gel in November 2022. Given the initial assessment, surgical interventions are indicated in this case. However, it's important to mention that non-surgical therapy has been repeated at the patient's request, with the idea of potentially reducing the number of teeth requiring surgical treatment.

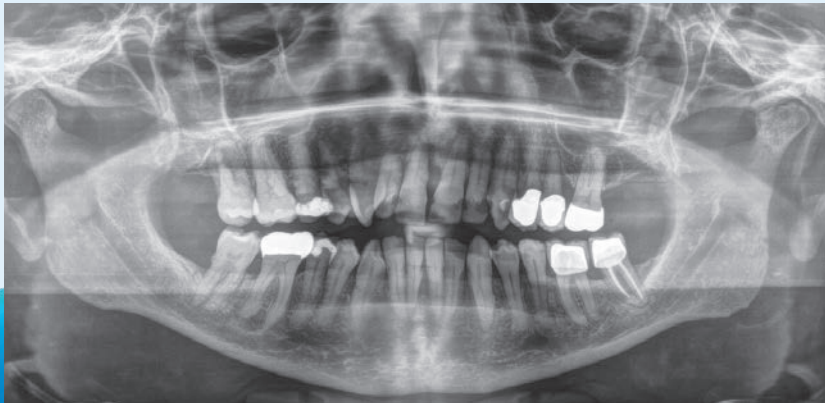

Follow-up examination after 5 months in April 2023. The results of this case were exceptionally favorable. The number of sites requiring surgical treatment was significantly reduced.

Insights from Prof. Dr. Peter Hahner



Prof. Dr. Peter Hahner,
Professor of Clinical Periodontology and
Prevention Management at EU FH,
Practice for Periodontology in Cologne



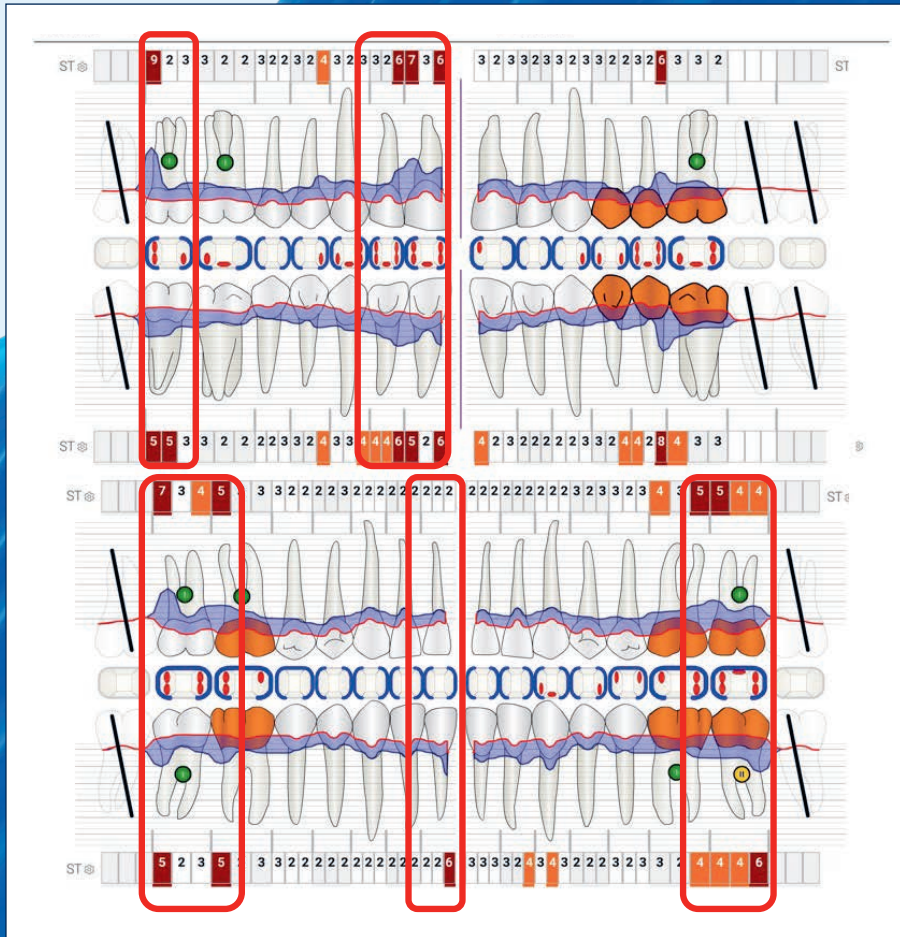
Patient assessment (born in 1962)

In the X-ray findings of this patient, vertical bone loss is evident in multiple teeth. As part of the non-surgical therapy (Stage 2 according to EFP Guidelines), Pocket-X® Gel was employed as a supporting adjunctive to mechanical debridement.

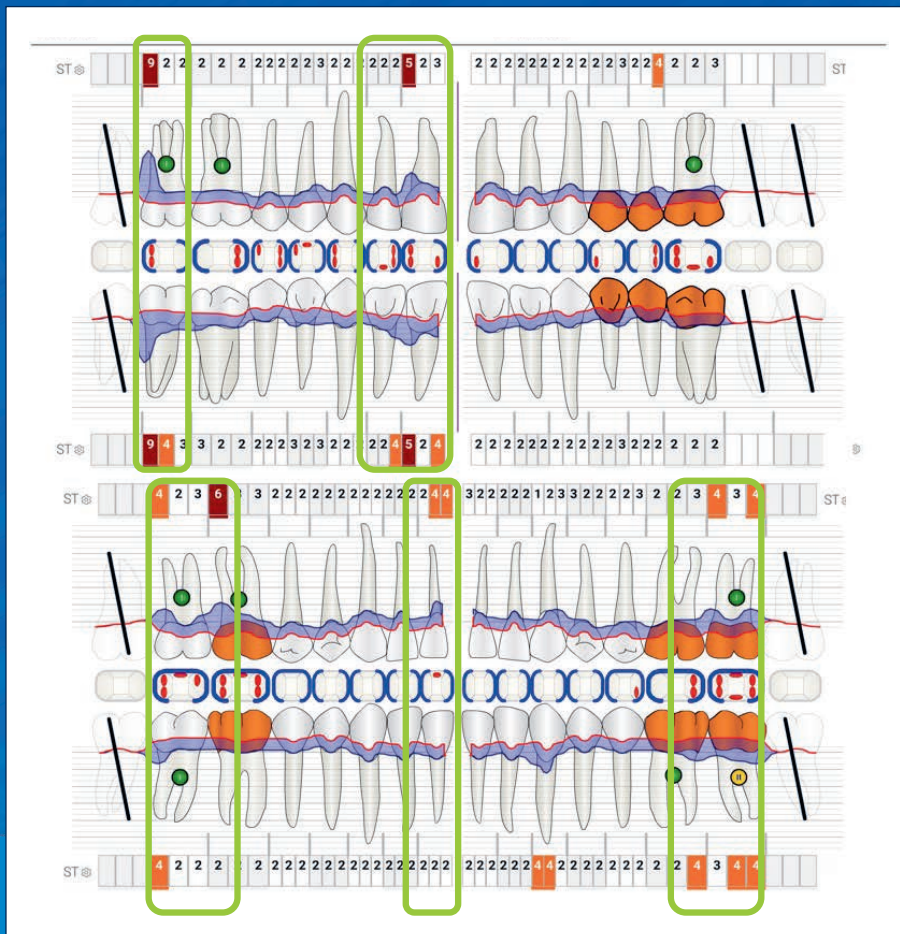
My Quote!

“An initial case series using Pocket-X® Gel has shown significant improvements in probing depths and attachment levels beyond what can be expected from conventional closed therapy. The combination of minimally invasive instrumentation and hyaluronic acid may even shift the current indication boundaries between non-surgical therapy alone and the inclusion of periodontal surgery.”





Findings and treatment (supra and subgingival mechanical plaque removal as part of initial therapy / stage 2), including the application of Pocket-X® Gel in October 2022.



Follow-up evaluation after 5 months in March 2023.

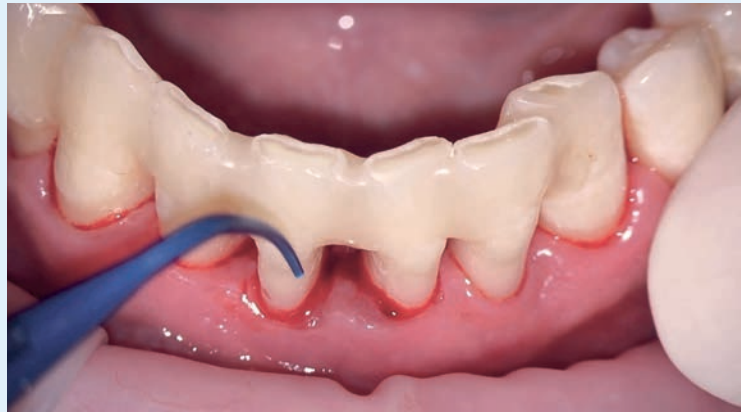Insights from Nico Menne



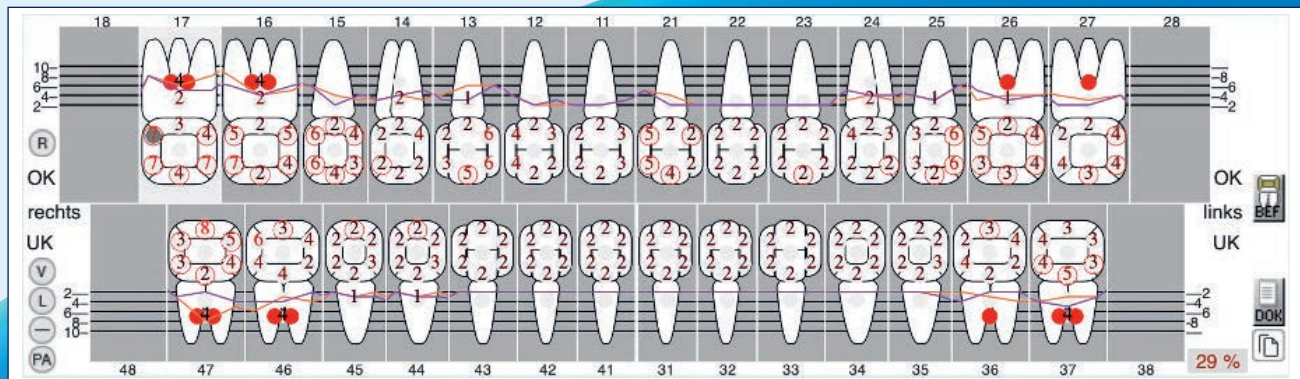
Nico Menne, Dentist,
Practice for Periodontology
and Prophylaxis in Koblenz

My tips for using Pocket-X® Gel:

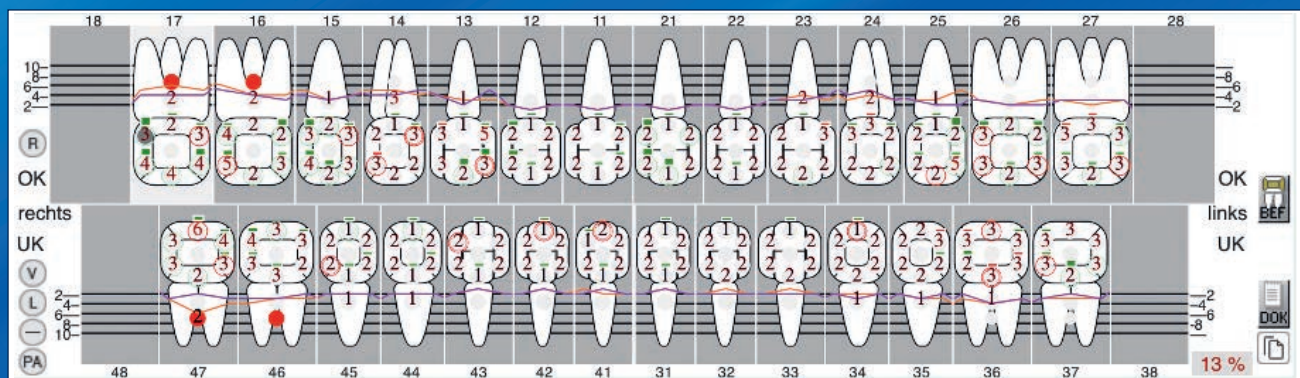
Storage and application of Pocket-X® Gel are straightforward. Using the included thin and flexible cannula, the gel is injected from the bottom of the pocket while gently retracting the cannula. Pocket-X® Gel, initially in liquid form in the syringe, gels at body temperature, ensuring stability within the pocket. Patient education about the recommended behavior, as per the IFU, is essential, such as gentle brushing in the first 2 days after use.



Case 1

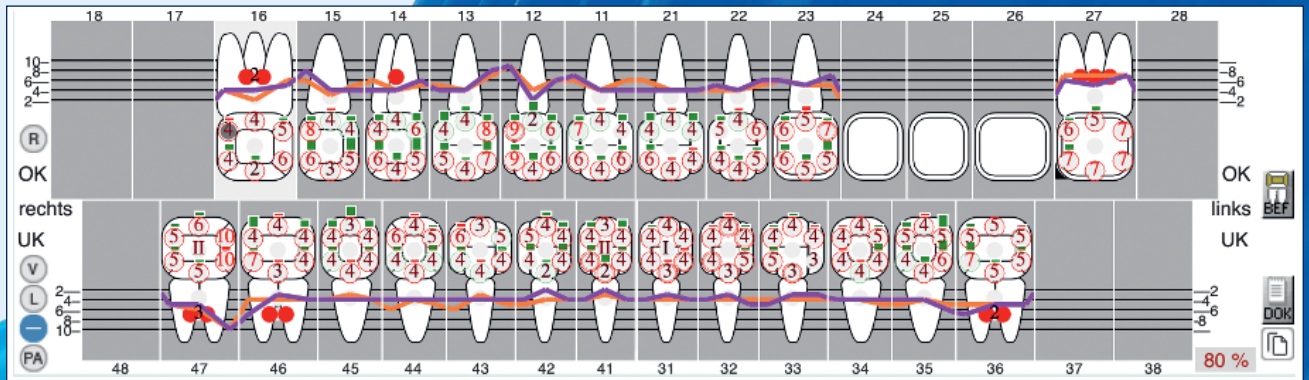


Initial assessment end of March 2023, application of Pocket-X® Gel adjunctive to subgingival instrumentation.

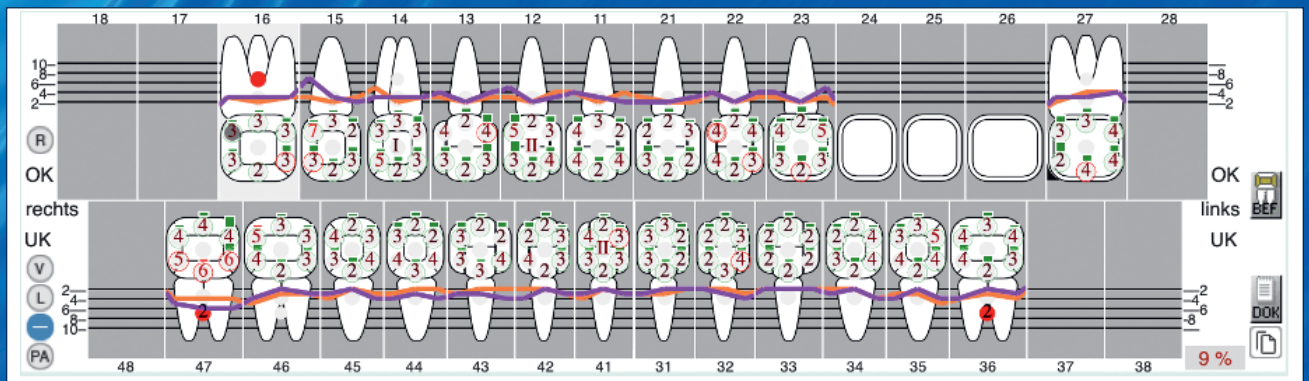


Treatment evaluation after 6 months, successful reduction of probing pocket depths.

Case 2



Initial assessment November 2021, application of Pocket-X® Gel adjunctive to subgingival instrumentation end of January.



Treatment evaluation 3.5 months after treatment; Bleeding on Probing was reduced from 80% to 9%.

My Quote!

“Besides the simple application with the flexible provided cannula during the initial periodontal therapy, I have noticed better results in BOP (Bleeding on Probing) and pocket depths during the treatment evaluation when using Pocket-X® Gel. Subjectively, the soft tissue appears firmer as early as the following day, wound healing seems accelerated, and reduced post-operative sensitivities are noted. I look forward to long-term results and further studies.”

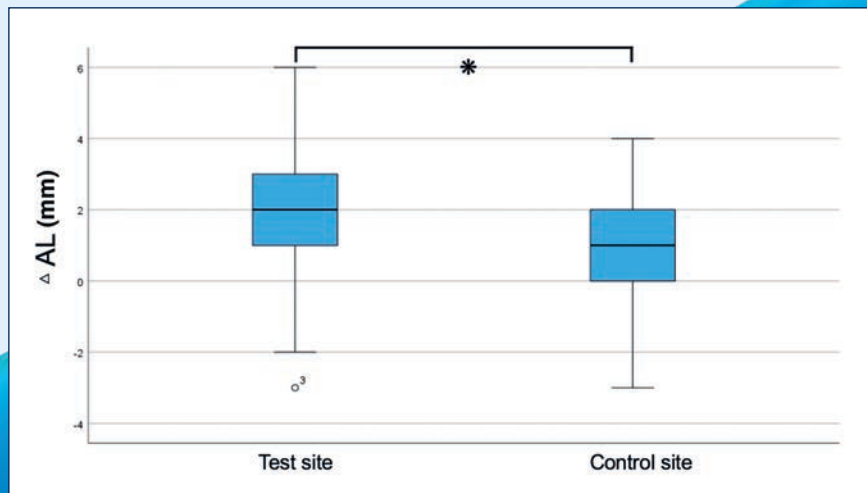
Insights from Dr. Florian Rathe



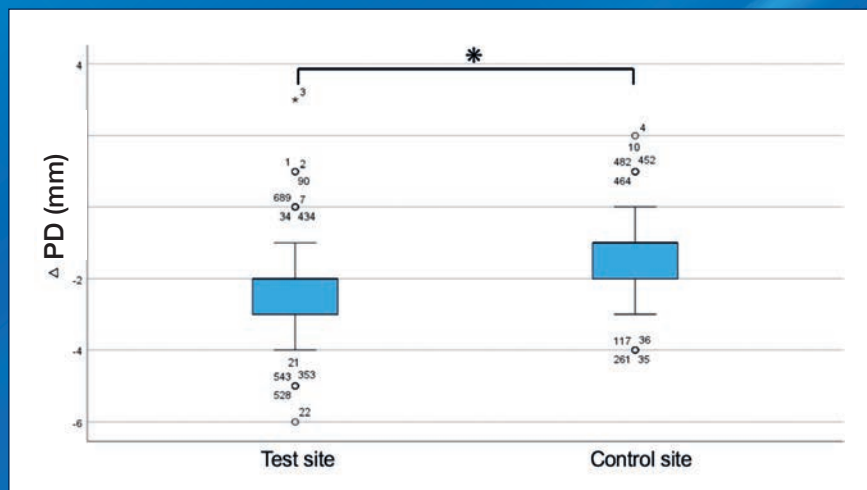
Dr. Florian Rathe, Specialist in Periodontology and Implantology, Practice Schlee & Rathe Forchheim; Lecturer and Researcher at DANUBE Private University Krems, Austria

Data from a retrospective analysis (not yet published)

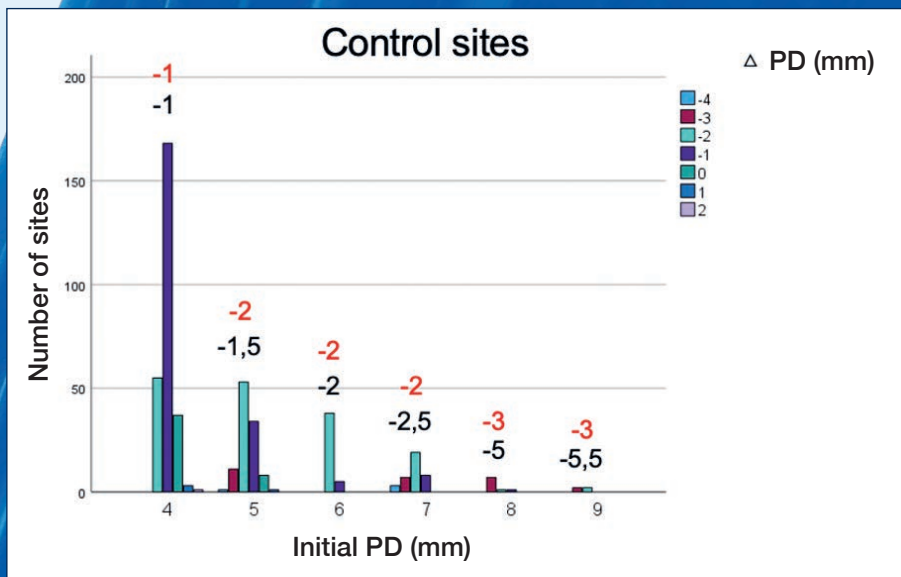
14 male and female patients were treated subgingivally in 4 sessions. During the final appointment, Pocket-X® Gel was applied following instrumentation of pockets with a depth of 4 mm or more. A “Split Mouth” approach was employed. A total of 315 test and 466 control sites were analyzed.



Graph 1
average attachment gain
(* = p < 0,0001)

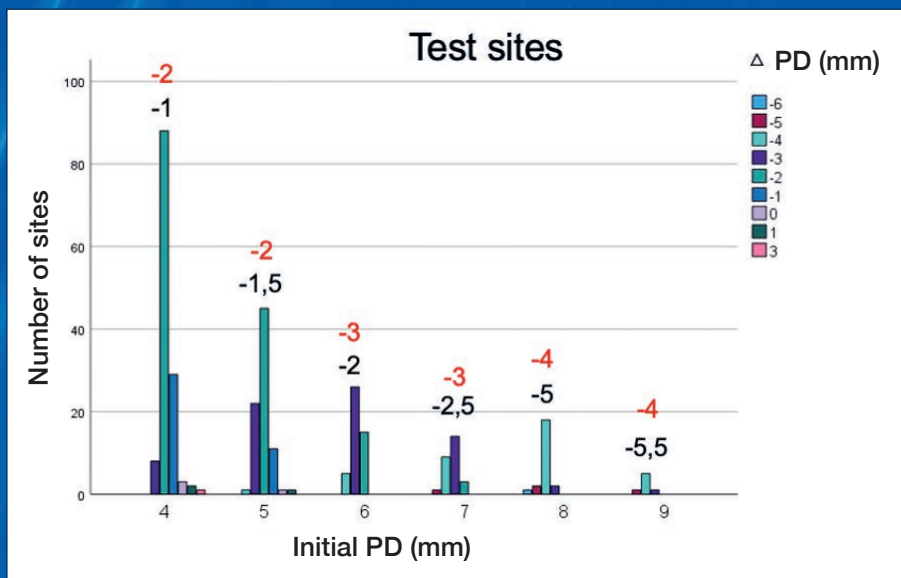


Graph 2
average reduction
of pocket depth
(* = p < 0,0001)



Graph 3

Reduction in probing depth in test and control sites, grouped by initial pocket depth in millimeters. Black = Expected reduction with instrumentation alone in mm; Red = Actual reduction in mm.



My
Quote!

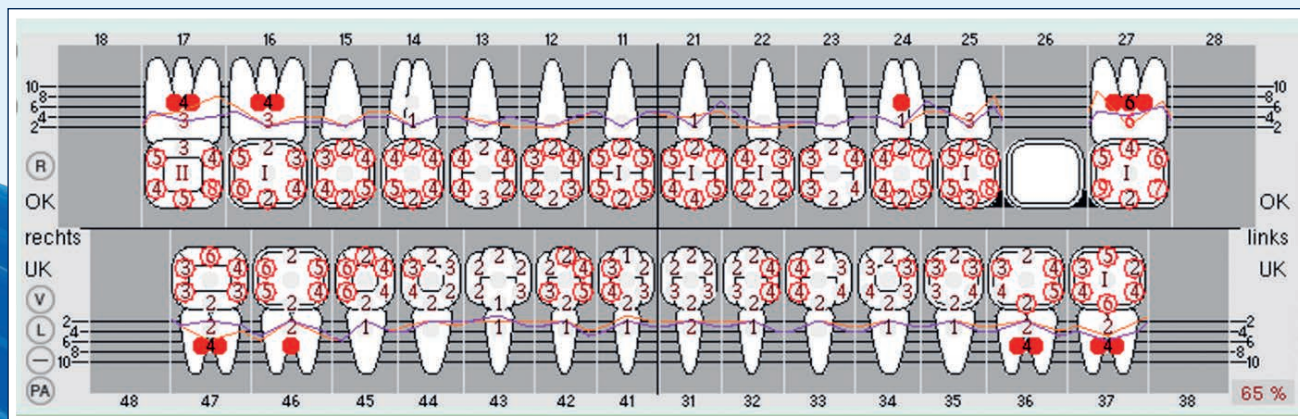
“I use Pocket-X® Gel in initial periodontitis therapy and supportive care because the combination of subgingival instrumentation and Pocket-X® Gel leads to significantly greater reductions in probing depth (red numbers in Graph 3) compared to the reduction in probing depth that can be expected after subgingival instrumentation alone (black numbers in Graph 3).”

Insights from Dr. Florian Rathe

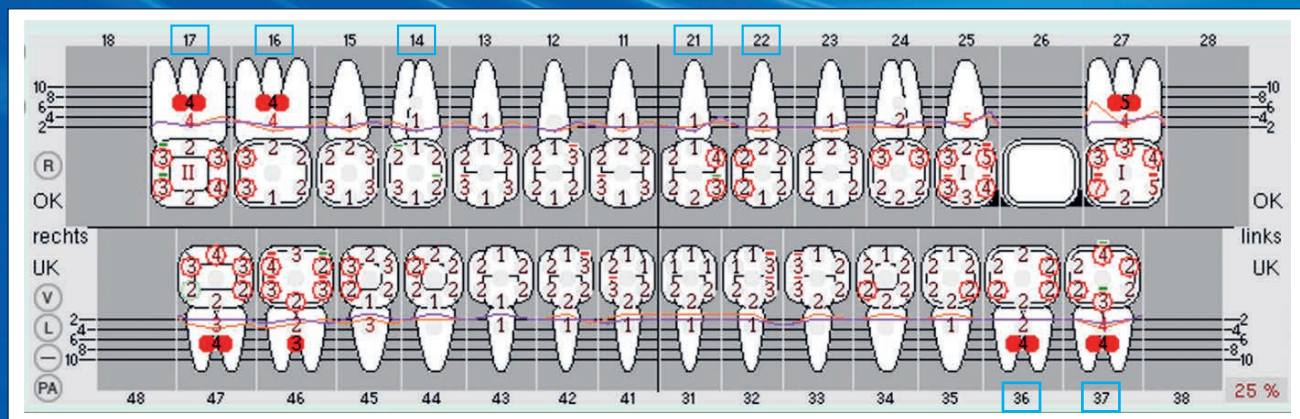


Two cases from the Schlee&Rathe clinic in Forchheim

Case 1

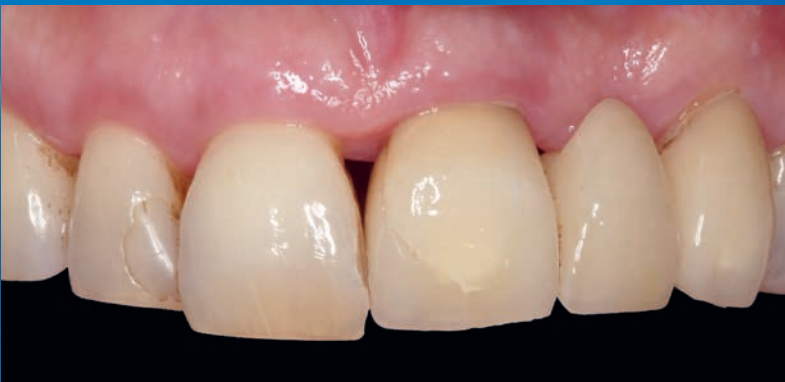
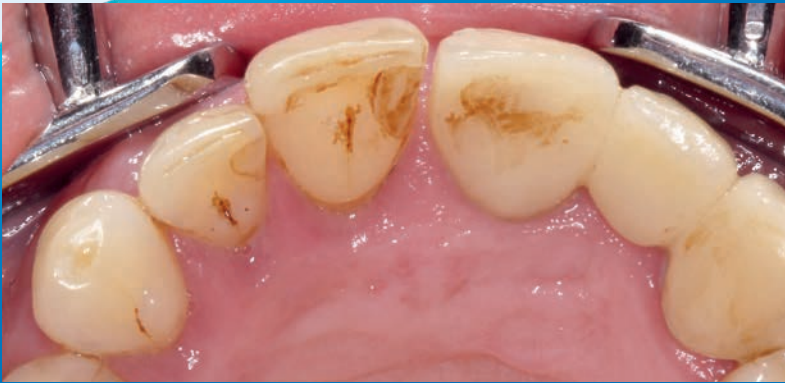
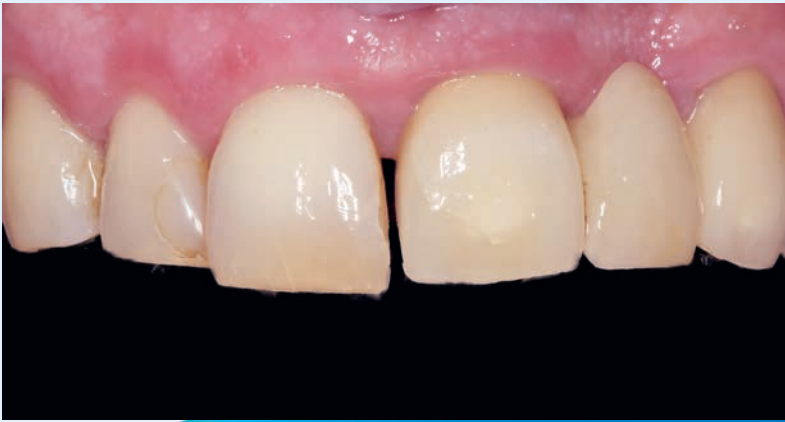Initial assessment from 28.03.2023



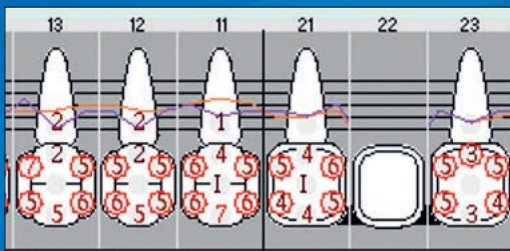
Reevaluation on 24.10.2023, 3 months after systematic periodontal therapy with a single application of Pocket-X® Gel (see marking, pockets ≥ 4 mm were treated). Noteworthy is the depth reduction in periodontal pockets treated with Pocket-X® Gel, which clearly exceeded the expected results in conventional therapy (see control sites).

Case 2

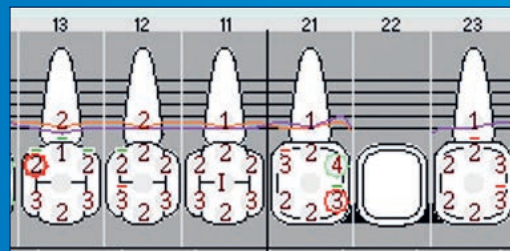


Assessment: The bridge from 21 to 23 was broken and couldn't be replaced due to active periodontitis. Tooth 11 had shifted buccally due to the pressure from severe palatal inflammation.

At the time of reevaluation, the inflammation had completely disappeared, and tooth 11 had spontaneously retroclined.



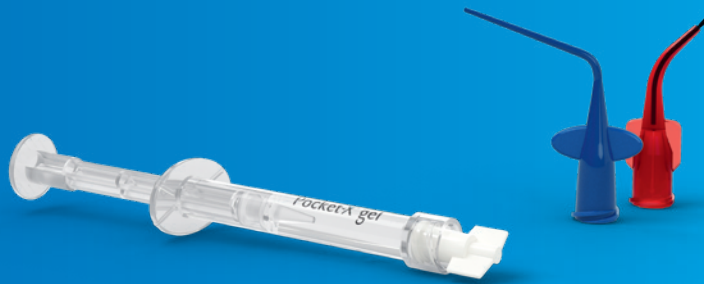Periodontal chart before treatment:
All pockets > 4 mm shown were instrumented subgingivally in four appointments, and during the last appointment, Pocket-X® Gel was applied once.



Results after treatment with instrumentation and Pocket-X® Gel.

Protect periodontal pockets and improve gingival healing with Pocket-X® Gel.

For treatment results you and your patients will love



Pocket-X® Gel is available in packs of 3 syringes, each containing 1.0 ml. One syringe is typically sufficient for several periodontal pockets in one patient (usually 5–10 pockets). For additional ease of application, a longer blue tip and a shorter red tip with a brush are included with each syringe.

Learn more

Discover Pocket-X® Gel, the innovative adjunctive for non-surgical periodontal therapy.



VISIT OUR WEBSITE!

Die Produktverfügbarkeit kann von Land zu Land unterschiedlich sein.



More details about our distribution partners:
www.geistlich-dental.com

Manufactured exclusively for Prudentix Ltd.

POB 799
Lod 7110604, Israel
www.prudentix.com

Manufacturer

Tree of Life Pharma Ltd.
POB 799
Lod 7110604, Israel

Distribution partner

Geistlich Pharma AG
Business Unit Dental
Bahnhofstrasse 40
6110 Wolhusen, Switzerland
www.geistlich-dental.com

Affiliate Germany

Geistlich Biomaterials
Vertriebsgesellschaft mbH
Schöckstrasse 4
76534 Baden-Baden
www.geistlich.de

Affiliate United Kingdom, Ireland

Geistlich Sons Limited
Thorley House
Bailey Lane
Manchester Airport
Manchester M90 4AB
www.geistlich.co.uk

Affiliate Italy

Geistlich Biomaterials Italia S.r.l.
Via Castelletto, 28
36016 Thiene VI
www.geistlich.it

Affiliate France

Geistlich Pharma France SA
Parc des Reflets
165 avenue du Bois de la Pie
CS 43073
95913 ROISSY CDG Cedex
www.geistlich.fr